
Case Report

A Giant Polypoid Basal Cell Carcinoma of the Lower Extremity

Farhad Handjani MD*, Shima Shahbaz MD*, Fatemeh Sari-Aslani MD**, Shahin Aghaei MD***, Ali Akbar Ali-Zadeh MD**

Less than 1% of basal cell carcinomas are giant basal cell carcinomas. Giant basal cell carcinomas are rare. They preferentially involve the trunk and are commonly associated with neglect. Giant basal cell carcinomas of 10 cm or greater are associated with a high rate of metastasis. We report a case of giant basal cell carcinoma of the leg which is not associated with neglect and no signs of metastasis, despite being more than 10 cm in diameter. The present paper includes a brief review of the literature.

Archives of Iranian Medicine, Volume 13, Number 2, 2010: 153 – 155.

Keywords: Basal cell carcinoma • giant • polypoid

Introduction

Basal cell carcinoma (BCC) is the most common malignancy of humans.¹ BCC frequently occurs on sun-exposed and sun-damaged skin. Most BCCs are less than 1 cm in diameter. Giant BCC is defined, by the American Joint Committee on Cancer, as a tumor larger than 5 cm in diameter. Less than 1% of all BCCs achieve this size.² Giant BCCs more commonly appear on the trunk and display a more aggressive behavior, resulting in local invasion and metastasis.³ Herewith, we report a case of giant BCC on the left lower extremity.

Case Report

A 65-year-old man from Afghanistan referred to Faghihi Hospital Dermatology Clinic with an ulcerative plaque on his leg for one-year duration. The lesion started as a small papule on the left lower leg and slowly progressed to a large plaque

which then ulcerated as it increased in size during a three month period.

The patient had complaints of mild pain while walking, with occasional bleeding and serous discharge from the lesion. He was not a smoker and had no history of trauma, burn or radiation exposure.

Physical examination revealed a dusky red to violaceous fungating and vegetative sessile plaque, 16×12 cm in diameter, over the medial aspect of the left lower leg (Figure 1). The center of the lesion was depressed and no satellite lesion(s) were present. Examination of the left inguinal area revealed no lymphadenopathy. A complete physical examination of all organs was performed with no detected abnormalities. Routine blood tests including complete blood count, erythrocyte sedimentation rate, liver function tests, blood urea nitrogen and creatinine were all within normal limits. In addition to the above examinations, a chest X-ray as well as an X-ray of the involved leg were performed with no reported abnormalities. Taking into account the results of all of the above examinations, no evidence of metastasis was detected.

A biopsy was taken from the lesion. Histopathological examination revealed infiltration of the dermis by variable sized nests of basaloid cells with peripheral palisading of the nuclei and focal artificial cleft formation (Figure 2). In the

Authors' affiliations: *Department of Dermatology, **Department of Pathology, Shiraz University of Medical Sciences, Shiraz, ***Department of Dermatology, Jahrom University of Medical Sciences, Jahrom, Iran.

Corresponding author and reprints: Farhad Handjani MD, Department of Dermatology, Shiraz University of Medical Sciences, Shiraz, Iran.

E-mail: hanjanif@yahoo.com

Accepted for publication: 8 April 2009

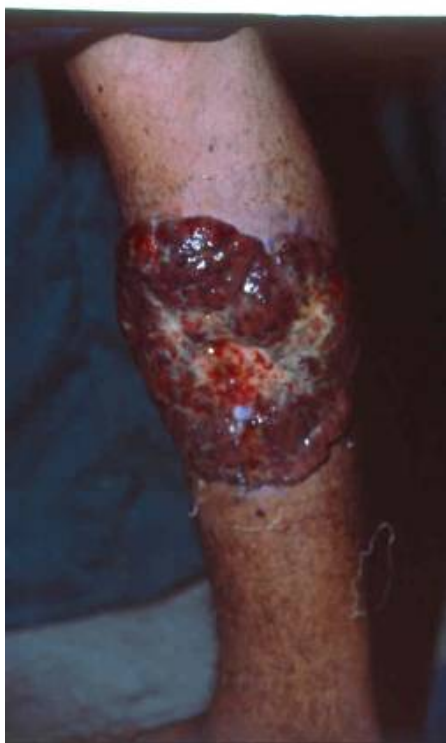

Figure 1. A vegetative sessile plaque with central depression on the medial side of the left lower leg

deep dermis, the tumor cells grew in small nests without palisading or clefting artifact. Pleomorphism and frequent mitotic figures were seen.

Consultation with a plastic surgeon led to complete excision of the lesion.

Discussion

BCC is the most common skin malignancy in Caucasians and is more common in males than females.⁴ Exposure to ultraviolet (UV) radiation is the primary etiologic agent for the development of BCC and accounts for the preferential distribution of these tumors over heavily sun-exposed areas of the body.⁵⁻⁶ Accordingly, about 80% of BCCs are located on the head and neck, 10% occur on the unexposed trunk, and only 8% of them are found in the lower limb.⁷ Other important pathogenic factors include advanced age, specific phenotype (fair complexions), genetic syndromes and polycyclic aromatic amines.⁸ These etiologic factors must be considered when encountering BCCs in non-sun-exposed areas including the leg. In our case, there was no history of trauma or war-injury and no exposure to any potential carcinogenic chemicals.

Giant BCCs are rare tumors representing less than 0.1% of all skin tumors.⁷ Different criteria

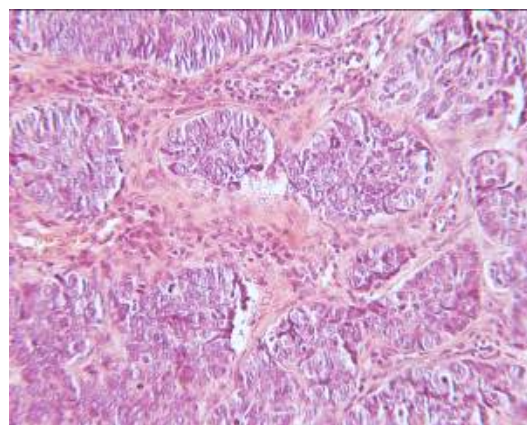


Figure 2. The nodules of basaloid cells without artificial clefts and only focal palisading of nuclei at the periphery of some of the nests (H&E ×100)

have been used to define giant BCC. Some have defined giant BCC as a tumor of 10 cm or larger in diameter.⁹ However, according to the American Joint Committee on Cancer classification, BCCs are defined as T1, if they are 2 cm or less in greatest diameter; T2, if they are more than 2 cm but not more than 5 cm in greatest diameter; and T3 or giant BCCs, if they are 5 cm or more in greatest diameter.¹⁰ There are rare reports of giant BCCs greater than 10 cm in diameter. They are frequently located on a patient's back because tumors in this site often go unnoticed by the patient. Skin malignancies, especially BCCs, rarely reach a large size on the lower limb.¹¹ In our case, the lesion was larger than 10 cm in diameter and occurred on the lower extremity rather than on the trunk.

Neglect and inadequate treatment of the primary lesion are the most important contributing factors to size in giant BCC.¹² In addition, there has been a strong association with chronic alcoholism and iron deficiency anemia.¹³⁻¹⁵ In our case, there was no evidence of neglect as he had referred to us less than a year after his lesion had appeared and there were no signs of chronic alcoholism or anemia. Moreover, patients who have a BCC with an aggressive histologic subtype, a history of radiation exposure and a recurrence after previous treatment are at risk for giant BCC.¹⁰ It has been shown that pre-existing cutaneous changes are possible factors in the pathogenesis of BCC on the lower extremities,¹⁶ although Betti et al. have disagreed with this proposition.¹⁷ Also, there are some reports of association of HPV with giant BCC.¹⁸ Finally, it has been stated that cigarette smoking is associated with an increased prevalence of BCC larger than 1.0 cm in

diameter.¹⁹

Giant BCC are of four clinical subtypes: exophytic (vegetant),²⁰⁻²¹ noduloulcerative,²² morpheaform¹⁰ and extensively ulcerative.²³⁻²⁴ The exophytic BCCs often have a polypoid appearance.²¹ The polypoid variant differs from other giant BCC in several ways: they appear on the torso or extremity, rather than the head or neck, the histologic type tends to be nonaggressive and the lesions are amenable to surgical cure with low metastatic potential.²⁵

Histological subtypes of giant BCC can be divided into nonaggressive: nodular and superficial subtypes, and aggressive: morpheaform, micronodular and metatypal subtypes.^{2,10} Our case revealed microscopic features of nodular BCC which were predominantly micronodular in the deep dermis, with no palisading of the cell nuclei at the periphery. Pleomorphism and frequent mitosis were seen.

In fact, giant BCCs are highly malignant, destructive tumors which often lead to metastasis and death. It has been stated that giant BCCs which reach a critical size of 10 cm in diameter almost always present with metastasis.³ However, we could not find any evidence of metastasis in our patient despite a complete work-up. Maybe this was attributable to the polypoid nature of the tumor which was associated with a low degree of metastatic potential as well as the favorable pathology of the lesion in our case.

Finally, it should be emphasized that early detection of these tumors by physicians or the patient as well as early surgical intervention could prevent tumor extension. Strategies to improve public awareness regarding the signs of skin cancer and careful screening examinations by all physicians are therefore recommended.

References

- 1 Miller DL, Weinstock MA. Nonmelanoma skin cancer in the United States: incidence. *J Am Acad Dermatol.* 1994; **30**: 774 – 778.
- 2 Randle HW. Basal cell carcinoma. Identification and treatment of the high-risk patient. *Dermatol Surg.* 1996; **22**: 255 – 261.
- 3 Mainella M, Majewski WT, Latkovich P, Michaels BM. Two giant basal cell carcinomas presenting simultaneously in the same patient, one resulting in lower extremity limb loss. *Ann Plast Surg.* 1998; **41**: 444 – 447.
- 4 Mackie RM. Basal cell carcinoma. In: Champion RH, Burton JL, Burns DA, Breathnach SM, eds. *Textbook of Dermatology.* 6th ed. Oxford: Blackwell Science Ltd; 1998: 1679 – 1685.
- 5 Gibson GE, Ahmed I. Perianal and genital basal cell carcinoma: a clinicopathologic review of 51 cases. *J Am Acad Dermatol.* 2001; **45**: 68 – 71.
- 6 Nahass GT, Blauvelt A, Leonardi CL, Penneys NS. Basal cell carcinoma of the scrotum. Report of three cases and review of the literature. *J Am Acad Dermatol.* 1992; **26**: 574 – 578.
- 7 Arnaiz J, Gallardo E, Piedra T, Sanz-Jimenez-Rico JR, Trillo Bohajar E, Alonso Pena D. Giant basal cell carcinoma on the lower leg: MRI finding. *J Plast Reconstr Aesthet Surg.* 2007; **60**: 1167 – 1168.
- 8 Lorenzini M, Gatti S, Giannitrapani A. Giant basal cell carcinoma of the thoracic wall: a case report and review of the literature. *Br J Plast Surg.* 2005; **58**: 1007 – 1010.
- 9 Salk WJ, Snow SN, Levine NS. Giant basal cell carcinoma. *J Am Acad Derm.* 1994; **30**: 856.
- 10 Randle HW, Roenigk RK, Brodland DG. Giant basal cell carcinoma (T3). *Cancer.* 1993; **72**: 1624 – 1630.
- 11 Kikuchi M, Yano K, Kubo T. Giant basal cell carcinoma affecting the lower abdominal, genital and bilateral inguinal regions. *Br J Plast Surg.* 2002; **55**: 445 – 448.
- 12 Randle HW. Giant basal cell carcinoma (letter). *Int J Dermatol.* 1996; **35**: 222 – 223.
- 13 Curry MC, Montgomery H, Winkleman RK. Giant basal cell carcinoma. *Arch Dermatol.* 1977; **113**: 316.
- 14 Wendt JR, Houck JP. A giant basal cell carcinoma with lymph node metastasis: a case report and review of the literature. *Contemp Surg.* 1988; **32**: 33.
- 15 Canterbury TDW, Wheeler WE, Madan E. Giant basal cell carcinoma of the back. *W V Med J.* 1990; **86**: 291.
- 16 Toshitatsu N, Tomoyuki K, Makoto K. Significance of pre-existing conditions in basal cell carcinoma on the lower extremities. *Int J Dermatol.* 1993; **32**: 350 – 353.
- 17 Betti R, Inselvini E, Perotta E, Crosti C. Pre-existing cutaneous changes in basal cell carcinoma of the lower extremities. *J Dermatol.* 1994; **21**: 738 – 740.
- 18 Northington M, Tamburin L, Hamza S, Diwan H, Skelton H, Smith K. Giant basal cell carcinoma associated with human papillomavirus infection. *J Cutan Pathol.* 2004; **31**: 174 – 178.
- 19 Smith JB, Randle HW. Giant basal cell carcinoma and cigarette smoking. *Cutis.* 2001; **67**: 73 – 76.
- 20 Manstein CH, Gottlieb N, Manstein ME, Manstein G. Giant basal cell carcinoma: a series of seven T3 tumors without metastasis. *Plast Reconstr Surg.* 2000; **106**: 653 – 656.
- 21 Gaughan LJ, Bergeron JR, Mullins JF. Giant basal cell epithelioma developing in acute burn site. *Arch Dermatol.* 1969; **99**: 594 – 595.
- 22 Betti R, Inselvini E, Moneghini L, Crosti C. Giant basal cell carcinomas: report of four cases and considerations. *J Dermatol.* 1997; **24**: 317 – 321.
- 23 Ko CB, Walton S, Keczek K. Extensive and fatal basal cell carcinoma: a report of three cases. *Br J Dermatol.* 1992; **127**: 164 – 167.
- 24 Sahl WJ Jr., Snow SN, Levine NS. Giant basal cell carcinoma. Report of two cases and review of the literature. *J Am Acad Dermatol.* 1994; **30**: 856 – 859.
- 25 McElroy J, Knight TE, Chang-Stroman L. Giant polypoid basal cell carcinoma. *Cutis.* 1996; **58**: 289 – 292.